

One-Stage Revision Arthroplasty for Infected Hip Replacements

Ernesto Muñoz-Mahamud^{*1,2}, Xavier Gallart¹ and Alejandro Soriano^{2,3}

¹Orthopaedics and Trauma Surgery Department, Hospital Clinic, University of Barcelona, C/Villarroel 170, Barcelona 08036, Barcelona, Spain

²Bone and Joint Infection Unit, Hospital Clinic, University of Barcelona, C/Villarroel 170, Barcelona 08036 Barcelona, Spain

³Infectious Diseases Department, Hospital Clinic, University of Barcelona, C/Villarroel 170, Barcelona 08036, Barcelona, Spain

Abstract: Infection remains a serious complication after total hip arthroplasty (THA) and is a leading cause of hip revision surgery. It is currently accepted that removal of the prosthesis is essential to curing an infection when facing chronic PJIs with prosthesis loosening. In order to avoid the disadvantages of a two-stage approach, some authors have proposed a one-stage hip revision for the treatment of hip prosthesis infection in selected patients using not only antibiotic-loaded cemented components but also cementless implant. In the case of a one-stage procedure, the patient is exposed to a single major procedure and therefore lower cumulative perioperative risk. A functional prosthesis replacement is completed without exposure to the complications associated with spacers. In addition, there are also benefits both financially and in terms of resource allocation.

Keywords: Infection, arthroplasty, hip, replacement.

INTRODUCTION

Infection remains a serious complication after total hip arthroplasty (THA) and is a leading cause of hip revision surgery. Despite correct surgical techniques and antibiotic prophylaxis, reported infection rates after THA remain between 1 to 3% [1, 2]. Up to approximately 30,000 THA are implanted annually in our country. Taking into account a 3% infection rate, a total of 3,000 cases per year of hip prosthesis infection are to be expected. Early diagnosis and treatment are mandatory to prevent an infection from becoming chronic and the corresponding hip replacement, which leads to higher morbidity and mortality as well as increased sanitary costs [3, 4].

Acute post-surgical prosthetic joint infection (PJI) can be treated correctly with surgical debridement and proper antibiotic therapy [5-8]. However, chronic PJIs imply high rates of relapse when treated with this strategy alone, even when antibiotic therapy is prolonged for months or even years [9, 10], and prosthesis removal is ultimately required [11]. The different response to treatment between acute and chronic PJIs may be related to the extension and maturity of the biofilm which covers the prosthesis. In view of the fact that surgical debridement in acute PJIs takes place before the biofilm has been formed and become stable, it is reasonable that debridement should also be more successful in this case.

It is currently accepted that removal of the prosthesis is essential to curing an infection when facing chronic PJIs

with prosthesis loosening [12, 13]. Currently, two-stage hip revision is advocated for in the treatment of chronic hip prosthesis infection [14, 15]. This strategy involves a first stage which consists in surgical debridement, prosthesis removal, implanting an antibiotic-loaded cement spacer and specific antibiotic therapy; the second stage takes place after the infection has been eradicated and consists in removing the hip spacer and implantation of the definitive prosthesis. However, this strategy has some drawbacks: its long duration delays the patient's recovery; it implies a high social and economic cost and is not exempt from complications [16]. The reported failure rates after two-stage hip revision range from 5 to 18% [17, 18].

In order to avoid the disadvantages of a two-stage approach, some authors have proposed a one-stage hip revision for the treatment of chronic hip prosthesis infection using not only antibiotic-loaded cemented components [13] but also cementless implants [16].

PATIENT SELECTION

It has been recommended that candidates for a one-stage hip revision meet the following criteria [13]: 1) absence of immunosuppression, 2) absence of clinical signs of active infection, 3) absence of fistulae, 4) absence of major soft tissue defect compromising wound closure and/or bone defect affecting implant stability, and 5) infection caused by low-virulence microorganisms.

PATIENT MANAGEMENT

Clinical Data

Patients typically report hip pain for more than two weeks, which may or may not be accompanied by local inflammatory signs. Symptoms or signs that may be found

*Address correspondence to this author at the Orthopaedics and Trauma Surgery Department, Bone and Joint Infection Unit, Hospital Clinic, University of Barcelona, C/Villarroel 170, Barcelona 08036, Barcelona, Spain; Tel: 00+34+932275400; Fax: 00+34+932279871; E-mail: e.munoz.mahamud@gmail.com

during physical examination include groin or knee pain, pain in response to motion exercises, inability to bear weight, swelling, erythema, pain with external rotation and flexion or even fistulae, despite the fact that these are more commonly found in acute PJIs. The presence of a cutaneous fistula is indeed a pathognomonic sign of infection. It is mandatory to perform a proper differential diagnosis that includes aseptic loosening.

Multiple complementary tests are available, but none of them are conclusive in and of themselves. Thus, the final diagnosis is usually obtained from the combination of a complete clinical history, an exhaustive physical examination, laboratory tests and image findings.

Laboratory Tests

Some laboratory markers suggest the presence of infection in a painful prosthesis. However, no laboratory parameter is pathognomonic of infection. Despite the fact that elevated values of white-blood cell count, C-reactive protein (CRP) and erythrocyte sedimentation rate (ESR) have been reported during PJI, these levels can vary widely [19]. In fact, there are no studies to determine which cutoff values may predict prosthetic infection. Greidanus *et al.* studied 151 patients who underwent revision of knee prosthesis with a pre-operative diagnosis of aseptic loosening. They performed intraoperative cultures and considered infection when 2 or more samples were positive for the same microorganism. Pre-operative laboratory findings were recorded and analyzed in correlation with the final diagnosis (septic or aseptic loosening). They suggested that CRP and ESR levels higher than 1.35 mg/dL and 22.5 mm/h respectively should lead to the suspicion of prosthetic infection.

Image Findings

Plain radiology is the first technique used for the assessment of a painful prosthesis, and is able to identify the cause of pain in 25% of cases since it can diagnose fractures, dislocations and heterotopic bone calcifications (Fig. 1).

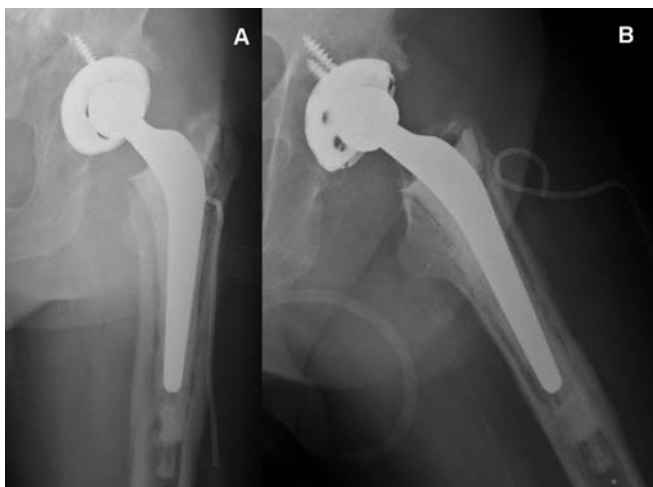


Fig. (1). Posteroanterior (A) and axial (B) view x-ray imaging of pelvis showing left hybrid total hip arthroplasty (non-cemented cup, cemented stem).

However, in most patients, the complication is due to septic or aseptic loosening, and this usually requires other

imaging tests to determine their aetiology [20]. Computed tomography (CT) and magnetic resonance have a diagnostic limitation in these patients due to the presence of artefacts created by the metallic components of the prosthesis. The combination of bone scintigraphy (BS) and ^{99m}Tc -HMPAO-labelled leukocyte scintigraphy (LS) is the most widely used imaging technique for the differential diagnosis of aseptic and septic loosening, providing a high sensitivity for detecting PJIs (Fig. 2).

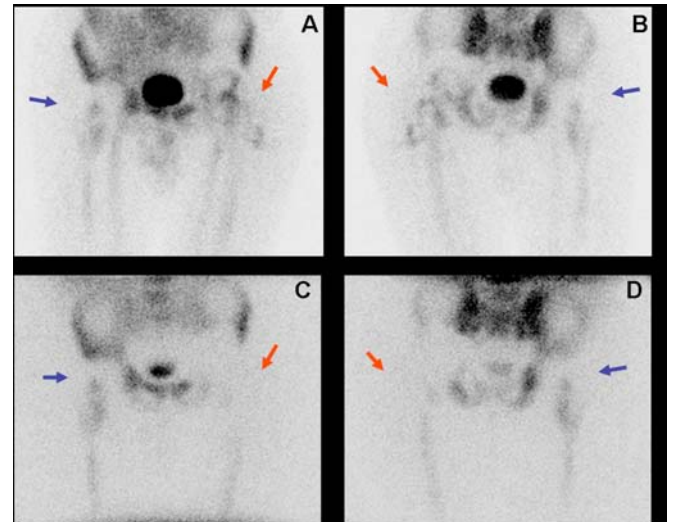


Fig. (2). The figure presents a patient with bilateral prosthesis and confirmed infection of the left hip. The leukocyte scintigraphy images (A: anterior, B: Posterior) show focal deposits in the left coxofemoral joint with fistulous trajectory towards the outer side of the thigh, inconsistent with the marrow scintigraphy (C: Anterior, D: Posterior), suggesting active infection (big arrows). Note that marrow scintigraphy findings are consistent with the leukocyte scintigraphy in the non-infected right hip prostheses (small arrows).

However, the specificity of LS is relatively low due to bone marrow activation when in contact with the prosthesis, in which case a focal deposit of labelled leukocytes falsely leads to the suspicion of infection of the prosthesis [20, 21]. It has been reported that ^{99m}Tc -colloid bone marrow scintigraphy (MS) may be useful for distinguishing an activated bone marrow from leukocyte deposits due to active infection [22, 23]. Further studies have been recently reported using other radiotracers including FDG-PET, ^{99m}Tc -ciprofloxacin and scintigraphy with anti-granulocyte antibodies [24, 25]. Nevertheless, experience with these agents is limited and further studies are needed to assess their usefulness.

Preoperative Microbiology

Pre-operative identification of the infecting microorganism is of paramount importance in the treatment protocol for chronic PJIs, since it enables selection of the most appropriate antibiotic treatment.

Culture of the synovial fluid obtained through hip aspiration is a useful technique not only to confirm the presence of microorganisms, but to identify the particular microorganism responsible for the infection. However, it is technically difficult to perform and is not exempt from either complications or false negative results. The technique is generally performed under fluoroscopic X-ray guidance. The

position of the needle can be confirmed by arthrography. In the past few years several articles have appeared on the usefulness of CT imaging (Fig. 3) in the evaluation of painful infection at the site of hip prosthesis before surgery [26].

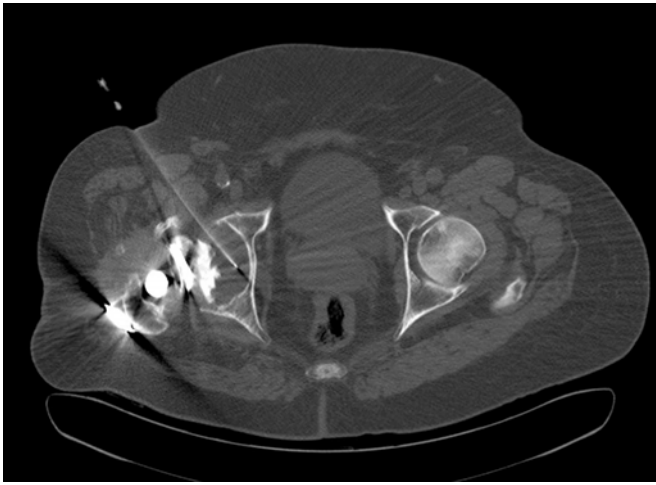

Fig. (3). An 79-year-old man with surgical confirmation of infected right hip prosthesis (*Staphylococcus epidermidis*). Axial CT image allowed confirming placement of the needle in the middle of the prosthetic fluid. Positive cultures to *Staphylococcus epidermidis* were obtained on CT-Aspiration.

However, joint aspiration has proven to have a broad range of sensitivity values and the frequency of dry-tap cases is not insignificant. In such dry-tap cases, percutaneous interface biopsy is a useful test for pre-operative isolation of the infecting microorganism [27].

Surgical Procedure

The patient is placed in a lateral position. Removal is always performed through pre-existing incisions. We routinely perform Hardinge's direct lateral approach, but have sometimes chosen the Watson-Jones modified by Röttinger approach as well as the posterolateral approach. When facing a difficult removal of the implant, a major trochanter osteotomy is performed using the Wagner technique with fenestrations in the anterior femoral diaphysis when necessary (Fig. 4). Necrotic tissue is excised and the

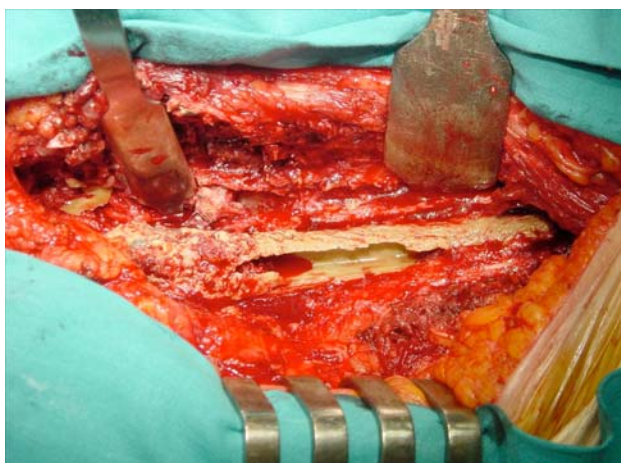


Fig. (4). Intraoperative image showing longitudinal Wagner's osteotomy in the femoral diaphysis.

wound is washed out with 10 liters of saline serum using either a high-pressure jet system or a conventional low-pressure system using bottles with no significant differences in both techniques [28].

Intraoperative Microbiology and Histology

Samples for the histological study were obtained from the periprosthetic membrane around the fracture [29, 30]. The samples were then fixed with formalin and embedded in paraffin; 4- μ m sections were cut and stained with hematoxylin-eosin.

The Pathology Department at our hospital follows Mirra's criteria (adapted by Feldman) [31, 32], according to which a sample is considered positive for infection when ≥ 5 neutrophils per high-power field (400x) are found in at least five separate microscopic fields (Fig. 5).

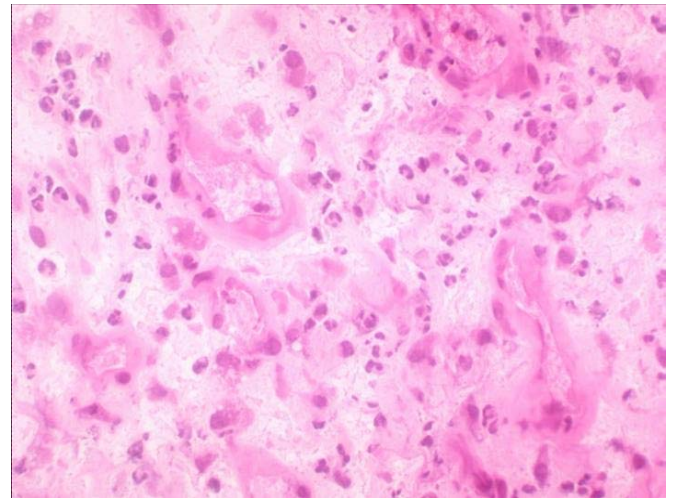


Fig. (5). Hematoxylin-eosin staining high-power microscopic field (400x) in which ≥ 5 neutrophils are found.

Samples for the microbiological study are always taken before the administration of antibiotic prophylaxis. At the time of prosthesis removal, at least six periprosthetic samples from different sites are submitted to the laboratory for culture.

Liquid samples aspirated from the surgical site with a sterile syringe are immediately inoculated into Batec 9000 Blood Culture Systems (Becton Dickinson Diagnostic Instruments, Sparks, Maryland) and incubated for five days [33]. Positive flasks are subcultured in aerobic and anaerobic agar media. Swab samples are obtained by passing a sterile swab (Delta-lab invasive sterile eurotube collection swab with Stuart transport medium; Rubí, Catalonia, Spain) over the areas of tissue, bone or fluid that are suspected of being infected. Solid periprosthetic tissue samples are immediately placed into a separate sterile universal bottle. Solid tissue samples and swab samples are cultured in both aerobic and anaerobic agar media and in thioglycolate broth enriched with vitamin K and hemin and are incubated for ten days. Positive cultures are sent for microorganism identification and sensitivity testing.

Follow-Up and Evaluation

After discharge, patients are seen monthly while they continue antibiotic treatment. Later, they have follow-up

visits every six months for a minimum of 24 months. At each visit, clinical response and adverse events are recorded. Outcome is classified as follows after the final visit: 1) cure, when the patient presents no local signs of inflammation and CRP remains below 1mg/dl; 2) failure, when these criteria are not met. At the final visit, functional results are determined according to the Merle d'Aubigne scale and the Harris Hip Score.

DISCUSSION

Chronic infection remains a serious complication of total hip arthroplasty (THA). Several techniques have been used with the following success rates [34, 35]: 1) 93% in two-stage replacement with antibiotic-loaded cement, 2) 86% in two-stage replacement either without cement or using plain cement only, 3) 86% in one-stage replacement with antibiotic-loaded cement, and 4) 59% in one-stage replacement either without cement or using plain cement only.

Although two-stage prosthesis revision has been advocated as the gold standard for the treatment of infected THA [12, 36], Vielpeau C. *et al.* [37] reported a similar rate of infection control with either one- or two-stage replacement. In this retrospective review carried out in 14 French teaching centres, 349 fully-documented patients were followed up for at least two years after exchange arthroplasty. A cure rate of 88% was achieved for 127 patients treated by direct exchange and 85% for 222 patients treated by a two-stage procedure. They highlighted three conclusions:

1. Similar success rates was observed when comparing one- and two-stage replacement (88% and 85%, respectively), as well as when comparing cementless prosthesis and those fixed with antibiotic-loaded cement (85% and 90%, respectively).
2. Mechanical complications rate was higher in the two-stage replacement group. In the study, complications requiring surgery were observed in 20% of patients in the two-stage group and only 9% of the patients in the one-stage group. The complications observed were leg-length discrepancy, aseptic loosening, fractures and dislocations.
3. The use of more invasive techniques was not associated with higher control of the infection. Femorotomy, which might be recommended so as to facilitate the removal of fully-coated ingrowth stems or adherent distal cement, had no influence on control of the infection. On the contrary, it was associated with a fracture rate of 14%.

More recently, a systematic review focused on reinfection rates comprising 62 relevant studies, showed that the overall rate of reinfection in patients with PJIs treated by one- or two-stage replacement was 8.6% (95% CI=4.5-13.9) and 10.2% (95% CI=7.7-12.9), respectively [38].

One-stage revision has obvious advantages in the management of infected THA, especially when performed on selected patients [39]. In fact, it has already been suggested that the overall balance of risk and benefit favours the one-stage approach over the two-stage approach for the treatment

of hip prosthesis infection. The optimal treatment must balance outcome and overall risk; success requires more than simply eradicating the infection. In the case of a one-stage procedure, the patient is exposed to a single major procedure and therefore lower cumulative perioperative risk. A functional prosthesis replacement is completed without exposure to the complications associated with spacers such as spacer dislocation, femoral fractures or allergic reactions to the antibiotic [35]. In addition, there are also benefits both financially and in terms of resource allocation.

Factors associated with poor outcome are polymicrobial infection, gram-negative microorganisms, methicillin-resistant *Staphylococcus aureus* (MRSA) and group D *Streptococcus* [40]. This approach has been often underrated because of fears of recurrent infection without the use of local antibiotics delivered by cement spacers. Several factors have been associated with a successful outcome: absence of wound complications after the initial THA, good general health, sensitive *Staphylococcus* or *Streptococcus spp.* and the infecting microorganism is sensitive to the antibiotic in the cement

For some authors, the need of bone graft or cementless implants represents a contraindication for one-stage revision [2, 40]. However, others have shown good results in these situations. Winkler *et al.* [41, 42] published outcomes of 37 patients who were treated with one-stage cementless hip prosthesis. An infection-free rate of 92% was reported with an average follow-up of 4.4 years. In this series, five cases of MRSA were successfully treated. They conclude that allograft bone may be impregnated with high loads of antibiotics using special incubation techniques. Yoo *et al.* [16] published a retrospective review of 12 patients treated with a variety of cementless implants. All in all, an 83.3% implant survival was reported after a mean follow-up of 3.6 years. There was one recurrence of infection and one aseptic loosening. Rudelli *et al.* [43] published the outcomes of 32 patients who were treated with one-stage revision using both cemented, cementless and hybrid prosthesis. Antibiotic-

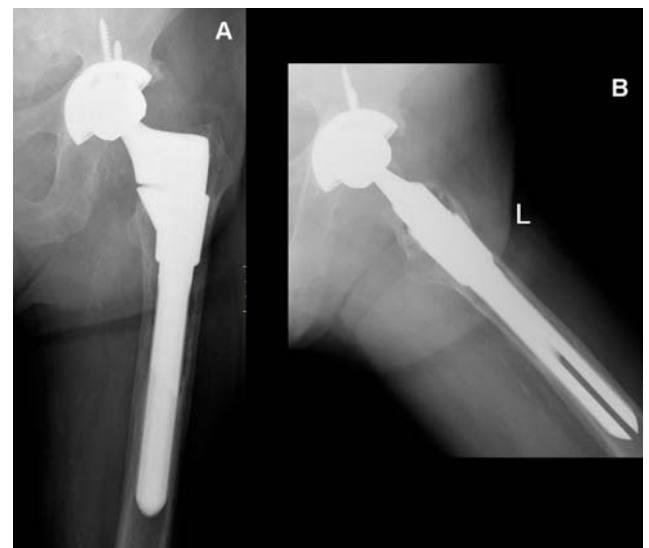


Fig. (6). Posteroanterior (A) and axial (B) view x-ray imaging of pelvis showing left cementless modular revision arthroplasty after 3 years of follow-up.

loaded cement was used with cemented prosthesis. They reported an infection-free rate of 93.7% after a mean follow-up of 103 months. García *et al.* [1] published a series of 14 patients with PJI treated with direct exchange, in which the femoral component was cemented in 7 cases and in 7 it was not cemented (Fig. 6). They reported no differences with regard to the clinical and microbiologic characteristics between both groups.

Surgeon training and experience should play a role in choosing the reconstruction option. Meticulous surgical debridement to clear dead space and residual bacterial colonization is emphasized by all authors. Antibiotic levels in the cement are limited as high levels can reduce mechanical integrity. Overall, it is unquestionable that a one-stage exchange, if successful, would provide the best benefit for both the patient and society. The benefits of one-stage revision make ongoing research worthwhile.

CONFLICT OF INTEREST

The authors confirm that this article content has no conflict of interest.

ACKNOWLEDGEMENTS

Declared none.

REFERENCES

- [1] García S, Soriano A, Esteban P, *et al.* Usefulness of adding antibiotic to cement in one stage exchange of chronic infection in total hip arthroplasty. *Med Clin (Barc)* 2005; 125(4): 138-9.
- [2] Schutzer SF, Harris WH. Deep-wound infection after total hip replacement under contemporary aseptic conditions. *J Bone Joint Surg Am* 1988; 70 (5): 724-7.
- [3] Barrack RL, Burnett RS, Sharkey P, Parvizi J. Diagnosing an infection: an unsolved problem. *Orthopedics* 2007; 30 (9): 777-8.
- [4] Martí-Valls J, Alonso J, Lamarca R, *et al.* Effectiveness and cost of total hip replacement in seven hospitals in Catalonia, Spain. *Med Clin (Barc)* 2000; 114(Suppl 2): 34-9.
- [5] Soriano A, García S, Bori G, *et al.* Treatment of acute post-surgical infection of joint arthroplasty. *Clin Microbiol Infect* 2006; 12 (9): 930-3
- [6] Soriano A, García S, Ortega M, *et al.* Treatment of acute infection of total or partial hip arthroplasty with debridement and oral chemotherapy. *Med Clin (Barc)* 2003; 121 (3): 81-5.
- [7] Vilchez F, Martínez-Pastor JC, García-Ramiro S, *et al.* Efficacy of debridement in hematogenous and early post-surgical prosthetic joint infections. *Int J Artif Organs* 2011; 34 (9): 863-9.
- [8] Martínez-Pastor JC, Muñoz-Mahamud E, Vilchez F, *et al.* Outcome of acute prosthetic joint infections due to gram-negative bacilli treated with open debridement and retention of the prosthesis. *Antimicrob Agents Chemother* 2009; 53 (11): 4772-7.
- [9] Goulet JA, Pellicci PM, Brause BD, Salvati EM. Prolonged suppression of infection in total hip arthroplasty. *J Arthroplasty* 1988; 3(2): 109-16.
- [10] Segreti J, Nelson JA, Trenholme GM. Prolonged suppressive antibiotic therapy for infected orthopedic prostheses. *Clin Infect Dis* 1998; 27 (4): 711-3.
- [11] Brandt CM, Duffy MC, Barbari EF, Hanssen AD, Steckelberg JM, Osmon DR. Staphylococcus aureus prosthetic joint infection treated with prosthesis removal and delayed reimplantation arthroplasty. *Mayo Clin Proc* 1999; 74(6): 553-8.
- [12] Bucholz HW, Elson RA, Engelbrecht E, *et al.* Management of deep infection of total hip replacement. *J Bone Joint Surg Br* 1981; 63(3): 342-53.
- [13] Ure KJ, Amstutz HC, Nasser S, Schmaizried TP. Directed-exchange arthroplasty for treatment of infection after total hip replacement. An average ten-year follow-up. *J Bone Joint Surg Am* 1998; 80 (7): 961-8.
- [14] Garvin KL, Fitzgerald RH, Salvati EA, *et al.* Reconstruction of the infected total hip arthroplasty with genatamicin-impregnated Palacos® bone cement. *Inst Course Lect* 1993; 42: 293-302.
- [15] Hsieh PH, Shih CH, Chang YH, Lee MS, Yang WE, Shih HN. Treatment of deep infection of the hip associated with massive bone loss: two-stage revision with an antibiotic-loaded interim cement prosthesis followed by reconstruction with allograft. *J Bone Joint Surg Br* 2005; 87(6): 770-5.
- [16] Yoo JJ, Kwon YS, Koo KH, Yoon KS, Kim YM, Kim HJ. One-stage cementless revision arthroplasty for infected hip replacements. *Int Orthop* 2009; 33(5): 1195-201.
- [17] Cabo J, Euba G, Saborido A, *et al.* Clinical outcome and microbiological findings using antibiotic-loaded spacers in two-stage revision of prosthetic joint infections. *J Infect* 2011; 63(1): 23-31.
- [18] Sorlí L, Puig L, Torres-Claramunt R, *et al.* The relationship between microbiology results in the second of a two-stage exchange procedure using cement spacers and the outcome after revision total joint replacement for infection: the use of sonication to aid bacteriological analysis. *J Bone Joint Surg Br* 2012; 94(2): 249-53.
- [19] Greidanus NV, Masri BA, Garbuz DS, *et al.* Use of Erythrocyte Sedimentation Rate and C-Reactive Protein Level to Diagnose Infection Before Revision Total Knee Arthroplasty. *J Bone Joint Surg Am* 2007; 89(7): 1409-16.
- [20] Benítez A, Muñoz A, Ricart Y, *et al.* What is the role of bone scintigraphy in the diagnosis of infected joint prostheses? *Nucl Med Commun* 2004; 25(5):527-32.
- [21] Fuster D, Duch J, Soriano A, *et al.* Potential use of bone marrow scintigraphy in suspected prosthetic hip infection evaluated with 99mTc-HMPAO-leukocytes. *Rev Esp Med Nucl* 2008; 27(6): 430-5.
- [22] Palestro CJ, Kim CK, Swyer AJ, Capozzi JD, Solomon RW, Goldsmith SJ. Periprosthetic indium-111-labelled leukocytes activity and complementary technetium-99m sulphur colloid imaging in suspected infection. *J Nucl Med* 1990; 31 (12): 1950-57.
- [23] King AD, Peters AM, Stuttle AWJ, Lavander JP. Imaging of bone infection with labelled white blood cells: role of contemporaneous bone marrow imaging. *Eur J Nucl Med* 1990; 17(3-4): 148-51.
- [24] Fuster D, Soriano A, García S, *et al.* Usefulness of 99mTc-ciprofloxacin scintigraphy in the diagnosis of prosthetic joint infections. *Nucl Med Commun* 2011; 32(1): 44-51.
- [25] Larikka MJ, Ahonen AK, Niemelä O, *et al.* Comparison of 99m Tc ciprofloxacin, ⁹⁹Tc white blood cell and three-phase bone imaging in the diagnosis of the hip prosthesis infection: improved diagnostic accuracy with extended imaging time. *Nucl Med Commun* 2002; 23 (7):655-61.
- [26] Tomas X, Bori G, Garcia S, *et al.* Accuracy of CT-guided joint aspiration in patients with suspected infection status post-total hip arthroplasty. *Skeletal Radiol* 2011; 40(1): 57-64.
- [27] Corona P, Gil E, Guerra E, *et al.* Percutaneous interface biopsy in dry-aspiration cases of chronic periprosthetic joint infections: A technique for preoperative isolation of the infecting organism. *Int Orthop* 2012; 36(6): 1281-6
- [28] Muñoz-Mahamud E, García S, Bori G, *et al.* Comparison of a low-pressure and a high-pressure pulsatile lavage during debridement for orthopaedic implant infection. *Arch Orthop Trauma Surg* 211; 131(9): 1233-8.
- [29] Bori G, Soriano A, García S, *et al.* Low sensitivity of histology to predict the presence of microorganisms in suspected aseptic loosening of a joint prosthesis. *Mod Pathol* 2006; 19 (6): 874-7.
- [30] Bori G, Soriano A, García S, Mallofré C, Riba J, Mensa J. Usefulness of histological analysis for predicting the presence of microorganisms at the time of reimplantation after hip resection arthroplasty for the treatment of infection. *J Bone Joint Surg Am* 2007; 89 (6): 1232-7.
- [31] Feldman DS, Lonner JH, Desai P, Zuokerman JD. The role of intraoperative frozen sections in revision total joint arthroplasty. *J Bone Joint Surg Am* 1995; 77(12): 1807-13.
- [32] Mirra JM, Amstutz HC, Matos M, Gold R. The pathology of the joint tissues and its clinical relevance in prosthesis failure. *Clin Orthop Relat Res* 1976; 117: 221-40.
- [33] Font-Vizcarra L, Garcia S, Martínez-Pastor JC, Sierra JM, Soriano A. Blood culture flases for culturing synovial fluid in prosthetic joint. *Clin Orthop Relat Res* 2010; 468 (8): 2238-43.
- [34] Langlais F. Can we improve the results of revision arthroplasty for infected total hip replacement. *J Bone Joint Surg Br* 2003; 85(5): 637-40

- [35] Jung J, Schmid NV, Kelm J, Schmitt E, Anagnostakos K. Complications after spacer implantation in the treatment of hip joint infections. *Int J Med Sci* 2009; 6(5): 265-73.
- [36] McDonald DJ, Fitzgerald RH, Ilstrup DM. Two-stage reconstruction of a total hip arthroplasty because of infection. *J Bone Joint Surg Am* 1989; 71(6): 828-34.
- [37] Vielpeau C, Lortat-Jacob A, Coll A. Management of the infected hip prostheses. *Rev Chir Orthop* 2002; 88(Suppl 1): 159-216.
- [38] Beswick AD, Elvers KT, Smith AJ, Goberman-Hill R, Lovering A, Blom AW. What is the evidence base to guide surgical treatment of infected hip prostheses? Systematic review of longitudinal studies in unselected patients. *BMC Med* 2012; 10(1): 18.
- [39] Raut VV, Siney PD, Wroblewski BM. One-stage revision of total hip arthroplasty for deep infection. Long-term follow-up. *Clin Orthop Relat Res* 1995; 321: 202-7.
- [40] Jackson WO, Schmalzried TP. Limited role of direct exchange arthroplasty in the treatment of infected total hip replacement. *Clin Orthop Relat Res* 2000; 381:101-5.
- [41] Winkler H. Rationale for one stage exchange of infected hip replacement using uncemented implants and antibiotic impregnated bone graft. *Int J Med Sci* 2009; 6(5): 247-52.
- [42] Winkler H, Stoiber A, Kaudela K, Winter F, Menschik F. One stage uncemented revision of infected total hip replacement using cancellous allograft bone impregnated with antibiotics. *J Bone Joint Surg Br* 2008; 90(12): 1580-4.
- [43] Rudelli S, Uip D, Honda E, *et al.* One-stage revision of infected total hip arthroplasty with bone graft. *J Arthroplasty* 2008; 23(8): 1165-77.

Received: January 4, 2013

Revised: January 7, 2013

Accepted: April 21, 2013

© Muñoz-Mahamud *et al.*; Licensee Bentham Open.

This is an open access article licensed under the terms of the Creative Commons Attribution Non-Commercial License (<http://creativecommons.org/licenses/by-nc/3.0/>) which permits unrestricted, non-commercial use, distribution and reproduction in any medium, provided the work is properly cited.