



# The Open Orthopaedics Journal

Content list available at: <https://openorthopaedicsjournal.com>



## LETTER

### Congenital Knee Dislocation: Which Classification to Follow?

Punit Tiwari<sup>1</sup> , Sergey S. Leonchuk<sup>2,\*</sup> , Harmeet Kaur<sup>3</sup>  and Gaurav Sharma<sup>1</sup> 

<sup>1</sup>Department of Orthopaedics, Maharishi Markandeshwar University of Health Sciences and Medical College, Kumarhatti, Solan, Himachal Pradesh, India

<sup>2</sup>Department of 6th orthopaedic, Russian Ilizarov Scientific Center for Restorative Traumatology and Orthopedics, Russian Federation, 6, M. Ulianova street, 640014, Kurgan, Russia

<sup>3</sup>AIIMS Bathinda, Bathinda, India

#### Article History

Received: February 04, 2020

Revised: April 02, 2020

Accepted: April 02, 2020

Congenital knee dislocation (CKD) was first reported by a Swiss physician Chatelaine, in the year 1822 [1], but even after the passage of two centuries, the exact treatment protocol is still debatable. CKD is a hyperextension deformity of the knee with anterior tibia displacement, present at birth. It may be idiopathic or syndromic (Larsen's syndrome, arthrogryposis multiplex congenita, myelomeningocele) [2 - 4]. The incidence of CKD is 1/100,000 in live births [5, 6]. To make it simple, it is 1% of the incidence of congenital hip dislocation [7, 8]. The exact etiology remains unknown. CDK manifests in the second half of pregnancy [9]. It has been associated with certain factors, including extrinsic factors such as intrauterine packaging disorders, breech presentations, and intrinsic factors like genetic malformation, but most of the cases are sporadic.

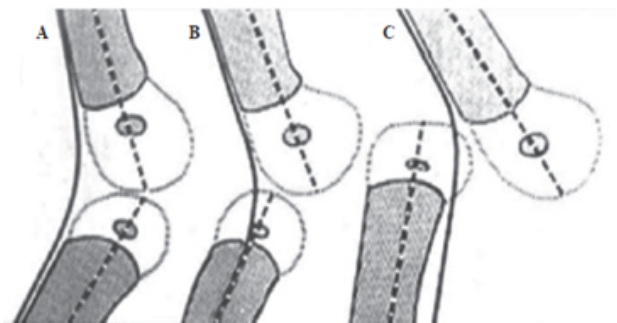
Neuromuscular imbalances have also been implicated to be a risk factor for CDK. In most cases, changes may occur in quadriceps muscles and cruciate ligaments, and even contractures may develop. The deformity may be unilateral or bilateral and mostly affect girls, but some literature reports equal distribution [1, 10, 11].

Orthopaedic surgeons have limited exposure to this deformity and only two major articles have been published in over the past decade proposing new or modified classifications for the management of CDK. Still, there is a lot of debate regarding which classification system to follow as treatment guidelines.

Which way forward?

Leveuf J. and Pais C. classification [12] separates the deformity into three subgroups (Fig. 1). Grade 1 is the most common type and not a true dislocation and accepted as conge-

nital hyperextension. Nearly 15 to 20° of hyperextension can be detected and passive range of flexion is maximum 90°. In Grade 2, congenital subluxation with joint incongruity is observed. Passive flexion of the knee is impossible and 25 to 40° of hyperextension can be achieved. In Grade 3, there is no contact between the joint surfaces of tibia and femur. This classification is based only on radiological views without an assessment of clinical manifestations.



**Fig. (1).** Leveuf J. and Pais C. classification of CKD: **A** - hyperextension, **B** - subluxation, **C** - dislocation.

Laurence classification is based only on a retrospective assessment of the success or failure of non-operative treatment [13], which cannot be used in planning of treatment tactics.

According to Abdelaziz T.H. grading system of CDK (Table 1), based on the initial range of passive knee flexion [2], serial casting is performed in patients with grade I (GI). In GII CDK in neonates (babies up to the age of 1 month), serial casting is started. A maximum of four weekly manipulations and castings are attempted. If a range of flexion >90° is achieved, serial casting is continued, but if the range of flexion remains <90°, it is necessary to proceed to PQR.

In babies older than 1 month, when first seen, percutaneous

\* Address correspondence to this author at the Department of 6th orthopaedic, Russian Ilizarov Scientific Center for Restorative Traumatology and Orthopedics, Russian Federation, 6, M. Ulianova street, 640014, Kurgan, Russia; Tel/Fax: +7 3522 454747, Mobile: +7 905 8516338; E-mail: [leon4yk@mail.ru](mailto:leon4yk@mail.ru)

quadriceps recession (PQR) is performed from the start. V-Y quadricepsplasty (VYQ) is indicated in patients with GIII CDK or in recurrent cases. We feel that age more than one month or grade III CKD itself should not be a qualifying criteria for PQR/VYQ, rather clinical examination and response to treatment should guide further management.

**Table 1. Abdelaziz T.H. CDK grading system.**

Grade	Range of Passive Flexion	Radiology
<b>GI</b>	>90°	Simple recurvatum
<b>GII</b>	30-90°	Subluxation/dislocation
<b>GIII</b>	<30°	Dislocation

According to Mehrafshan M. et. al. [14] reduction and stability criteria, there are 3 types of CKD. Type I is easily reducible CDK, with reduction snap when the femoral condyles pass in flexion, remaining stable. Type II is “recalcitrant” dislocation, reducible by posteroanterior “piston” but unstable, with iterative dislocation once posteroanterior pressure on the condyles is relaxed. Type III is irreducible dislocation.

This classification of CDK, based on neonatal clinical examination ahead of any treatment, looks promising and has better prognostic value. Initial examination also notes the number of transverse anterior skin grooves, range of motion (hyperextension, maximum flexion and global range: flexion + extension). The greater the number of anterior skin grooves, the more recent the in utero origin of dislocation, while the absence of grooves indicates long-standing dislocation. Flexion is more impaired in type III than type II and less impaired in type I, which corresponds to quadriceps retraction and also indicates the duration of in utero dislocation.

We found Mehrafshans’ classification more practical and having better prognostic value. In our opinion, the treatment of children with CKD should be started early after detailed clinical assessment with conservative methods, including serial manipulation and casting. Surgical interventions like V-Y quadricepsplasty (VYQ), percutaneous quadriceps recession (PQR), and other soft tissue procedures should be reserved for resistant cases and for older age children. Over the age of 2 years, the Ilizarov apparatus can be used for stiff knee deformity [15].

#### FUNDING

None.

#### CONFLICT OF INTEREST

The author declares no conflict of interest, financial or otherwise.

#### ACKNOWLEDGEMENTS

Declared none.

#### REFERENCES

- [1] Katz MP, Grogono BJ, Soper KC. The etiology and treatment of congenital dislocation of the knee. *J Bone Joint Surg Br* 1967; 49(1): 112-20. [http://dx.doi.org/10.1302/0301-620X.49B1.112] [PMID: 6019376]
- [2] Abdelaziz TH, Samir S. Congenital dislocation of the knee: a protocol for management based on degree of knee flexion. *J Child Orthop* 2011; 5(2): 143-9. [http://dx.doi.org/10.1007/s11832-011-0333-7] [PMID: 22468158]
- [3] Curtis BH, Fisher RL. Heritable congenital tibiofemoral subluxation. Clinical features and surgical treatment. *J Bone Joint Surg Am* 1970; 52(6): 1104-14. [http://dx.doi.org/10.2106/00004623-197052060-00003] [PMID: 4318392]
- [4] Kaissi AA, Ganger R, Klaushofer K, Grill F. The management of knee dislocation in a child with Larsen syndrome. *Clinics (São Paulo)* 2011; 66(7): 1295-9. [http://dx.doi.org/10.1590/S1807-59322011000700030] [PMID: 21876991]
- [5] Shah NR, Limpaphayom N, Dobbs MB. A minimally invasive treatment protocol for the congenital dislocation of the knee. *J Pediatr Orthop* 2009; 29(7): 720-5. [http://dx.doi.org/10.1097/BPO.0b013e3181b7694d] [PMID: 20104152]
- [6] Oetgen ME, Walick KS, Tulchin K, Karol LA, Johnston CE. Functional results after surgical treatment for congenital knee dislocation. *J Pediatr Orthop* 2010; 30(3): 216-23. [http://dx.doi.org/10.1097/BPO.0b013e3181d48375] [PMID: 20357585]
- [7] Drennan JC. Congenital dislocation of the knee and patella. *Instr Course Lect* 1993; 42: 517-24. [PMID: 8463700]
- [8] Jacobsen K, Vopalecky F. Congenital dislocation of the knee. *Acta Orthop Scand* 1985; 56(1): 1-7. [http://dx.doi.org/10.3109/17453678508992968] [PMID: 3984696]
- [9] Rumiantcev NJ, Kruglov IJ, Omarov GG. Congenital dislocation of the knee: prenatal diagnostics and treatment at an early age. *Pediatric Traumatology. Orthopaedics and Reconstructive Surgery* 2017; 5(2): 26-35. [http://dx.doi.org/10.17816/PTORS5226-35]
- [10] Cheng CC, Ko JY. Early reduction for congenital dislocation of the knee within twenty-four hours of birth. *Chang Gung Med J* 2010; 33(3): 266-73. [PMID: 20584504]
- [11] Madadi F, Tahririan MA, Karami M, Madadi F. Complicated congenital dislocation of the knee: A case report. *Arch Bone Jt Surg* 2016; 4(4): 396-8. [PMID: 27847857]
- [12] Leveuf J, Pais C. Les dislocations congénitales du genou. *Rev Chir Orthop Repar Appar Mot* 1946; 32: 313-50.
- [13] Laurence M. Genu recurvatum congenitum. *J Bone Joint Surg Br* 1967; 49(1): 121-34. [http://dx.doi.org/10.1302/0301-620X.49B1.121] [PMID: 6019377]
- [14] Mehrafshan M, Wicart P, Ramanoudjame M, Seringe R, Glorion C, Rampal V. Congenital dislocation of the knee at birth - Part I: Clinical signs and classification. *Orthop Traumatol Surg Res* 2016; 102(5): 631-3. [http://dx.doi.org/10.1016/j.otsr.2016.04.008] [PMID: 27266619]
- [15] Leonchuk SS, Novikov KI, Subramanyam KN, Shikhaleva NG, Pliev MK, Mundargi AV. Management of severe congenital flexion deformity of the knee using Ilizarov method. *J Pediatr Orthop B* 2020; 29(1): 47-52. [http://dx.doi.org/10.1097/BPB.0000000000000601] [PMID: 30807513]