



RESEARCH ARTICLE

Cadaveric Anatomical Study of Sural Nerve: Where is The Safe Area for Endoscopic Gastrocnemius Recession?

Alvin Chin Kwong Tan^{1,*}, Zhi Hao Tang² and Muhammad Farhan Bin Mohd Fadil¹

¹Department of Orthopaedic Surgery, Khoo Teck Puat Hospital, 90 Yishun, Central Singapore, 768828, Singapore

²Department of Orthopaedic Surgery, Tan Tock Seng Hospital, 11 Jalan Tan Tock Seng Singapore, 308433, Singapore

Received: July 18, 2017

Revised: August 18, 2017

Accepted: September 9, 2017

Abstract:

Purpose:

To ascertain in cadavers where the sural nerve crosses the gastro-soleus complex and where the gastrocnemius tendon merges with the Achilles tendon in relation to the calcaneal tuberosities.

Methods:

Twelve cadaveric lower limbs (6 right and 6 left) were dissected. The distances between the calcaneal tuberosities and the lateral border of the Achilles tendon where the sural nerve crosses from medial to lateral, as well as to the gastrocnemius tendon insertion into the Achilles tendon, were measured.

Results:

The mean and median longitudinal distances from the calcaneal tuberosity to where the sural nerve crosses the lateral border of the Achilles tendon are 9.9cm and 10cm respectively (range 7cm to 14cm). The mean and median longitudinal distances from the calcaneal tuberosity to where the gastrocnemius tendon inserts into the Achilles tendon are 19.9cm and 18.5cm (range 17cm to 25cm) respectively.

Conclusion:

It is generally safe to place the posterolateral incision more than 14cm above the calcaneal tuberosity to avoid the sural nerve if surgeons plan to use a posterolateral incision for endoscopic recession. The distance between the calcaneal tuberosity to the gastrocnemius tendon insertion into the Achilles tendon is too highly variable to be used as a landmark for locating the gastrocnemius insertion.

Keywords: Gastrocnemius recession, Sural nerve, Calcaneal tuberosity, Gastrocnemius tendon, Achilles tendon.

1. INTRODUCTION

The gastrocnemius recession was originally described to treat isolated gastrocnemius contractures in the paediatric population with neuromuscular disorders [1]. This procedure is now also being performed for gastrocnemius contractures in adults with conditions such as symptomatic hallux valgus, pes planus and plantar fasciitis [2 - 4].

Both open and endoscopic techniques can be used for gastrocnemius recession [5]. The Strayer [1] and Baumann [6] open procedures describe gastrocnemius fascia recession at different levels. The incision for performing the Strayer procedure is made 2cm distal to the gastrocnemius indentation, and the gastrocnemius fascia is sectioned 1 to 2 fingerbreadths distal to the musculotendinous junction. The incision for the Baumann procedure is over the proximal

¹ Address correspondence to this author at the Department of Orthopaedic Surgery, Khoo Teck Puat Hospital, 90 Yishun Central Singapore 768828, Singapore, Tel: +6565558000, E-mail: tan.alvin.ck@alexandrahealth.com.sg

medial calf, where the deep surface of the gastrocnemius muscle is sectioned. The Vulpius procedure is a gastrocnemius-soleus recession done for plantarflexion contractures with both the gastrocnemius fascia and the soleus muscle sectioned [7].

But while the open gastrocnemius recession techniques have been the traditional gold standard, endoscopic techniques have gained popularity with its purported advantages of a smaller incision, better cosmesis and faster recovery [8]. Performing an endoscopic gastrocnemius recession involves placing a posteromedial and/or posterolateral portal over the calf 12cm to 14 cm above the calcaneal tuberosity. After the development of tissue planes, a cannula is advanced; through which an endoscope is introduced. The tendon is then transected under direct vision of the endoscope.

Owing to the limited endoscopic visualization, iatrogenic injuries to the sural nerve is one of the potential surgical complications [9]. The reported rate of sural nerve injuries ranges from 2% (open) to 16% (endoscopic)[10].

Our study aims to ascertain where the sural nerve crosses the gastro-soleus complex and where the gastrocnemius tendon merges with the Achilles tendon in relation to the calcaneal tuberosities. Better understanding of the anatomy of the sural nerve in relation to the gastro-soleus complex can decrease the risk of the injury.

2. MATERIALS AND METHODS

12 fresh frozen cadaveric adult human lower limbs were used for this study. The gastrocnemius origin from the posterior femoral condyle, as well as the knee and ankle joints were intact for each of the dissected specimens.

Dissection and measurement of the cadaveric limbs were carried out by a single, fellowship trained Orthopaedic Surgeon. The limbs were placed in a prone position. A generous midline longitudinal incision was made from the middle of the popliteal fossa to the calcaneal tuberosity for each limb. The gastrocnemius muscles, gastrocnemius tendons and the insertion of the Achilles tendons into the calcaneal tuberosity were visualized. The sural nerve was also identified, explored and its course visualized for all 12 legs. The distances from the calcaneal tuberosity to where the sural nerve crosses the lateral border of the Achilles tendon (Fig. 1) as well as the distances from the calcaneal tuberosity to where the gastrocnemius tendon inserts into the Achilles tendon (Fig. 2) were recorded.

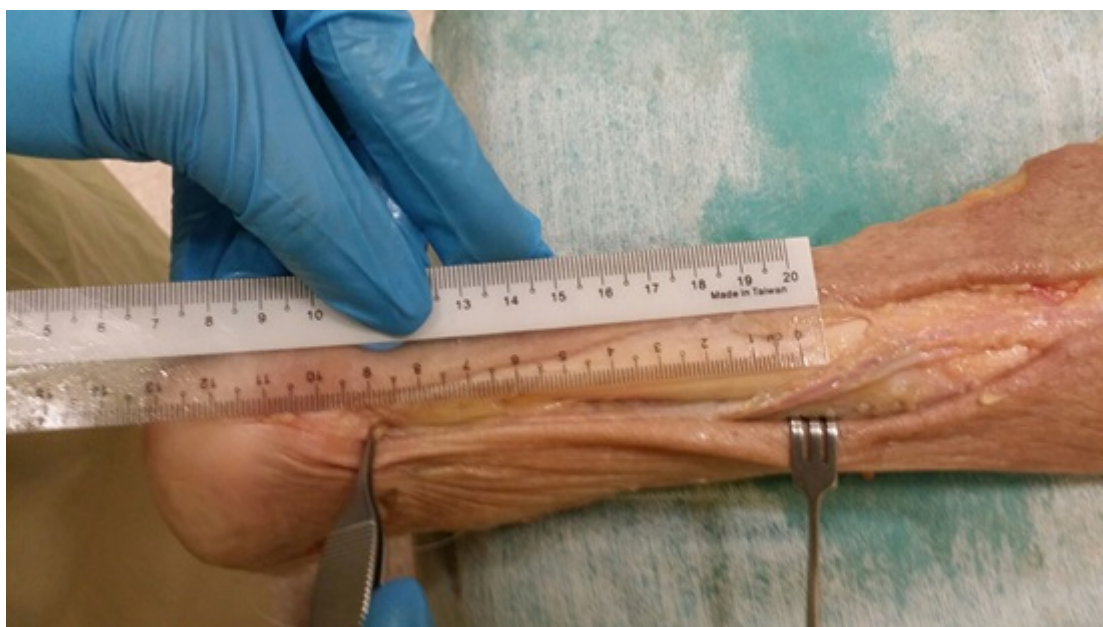

Fig. (1). Measurement from the calcaneal tuberosity to where the sural nerve crosses the lateral border of the Achilles tendon.

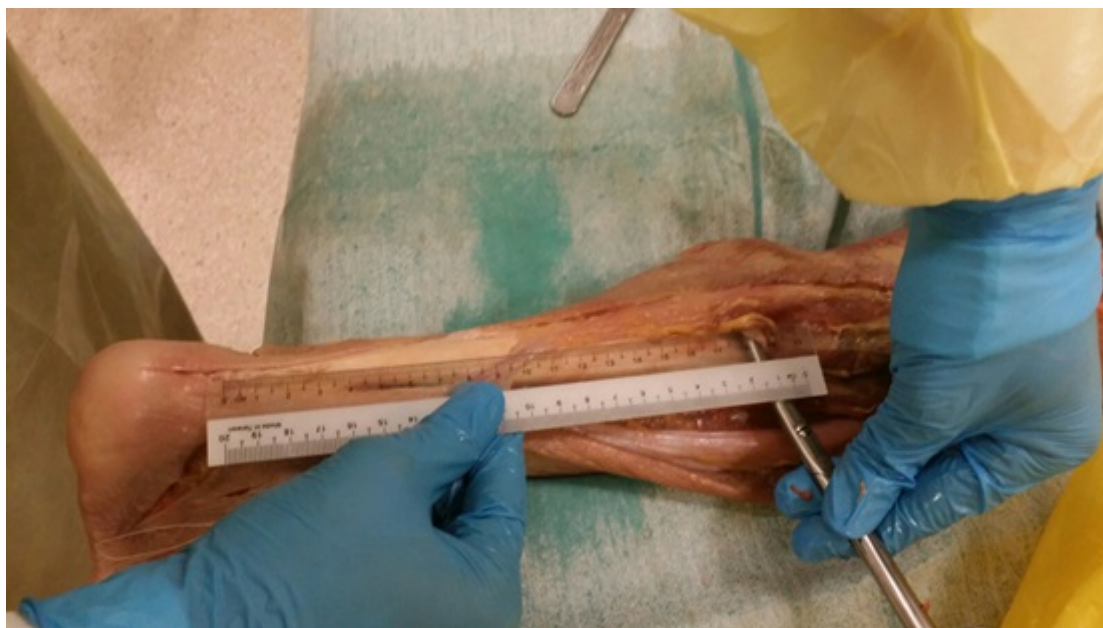

Fig. (2). Measurement from the calcaneal tuberosity to point of insertion of the gastrocnemius tendon into the Achilles tendon.

3. RESULTS

12 lower limb specimens (6 left and 6 right) were dissected and examined. There were 6 limbs from male cadavers, 1 limb from a female cadaver and 5 limbs from cadavers of unknown gender. As isolated lower limb specimens were used for this study, other anthropometric data were not available to us. The mean and median longitudinal distances from the calcaneal tuberosity to where the sural nerve crosses the lateral border of the Achilles tendon are 9.9cm and 10 cm, respectively (range 7 to 14cm). The mean and median longitudinal distances from the calcaneal tuberosity to where the gastrocnemius tendon inserts into the Achilles tendon are 19.9cm and 18.5cm (range 17 to 25cm), respectively.

4. DISCUSSION

The gastrocnemius originates from the posterior aspect of the femur, crossing the knee joint to insert into the calcaneal tuberosity *via* the Achilles tendon. The soleus muscle does not cross the knee joint as it arises from the posterior aspect of the tibia, the fibula and the interosseous membrane. It also inserts into the calcaneal tuberosity *via* the Achilles tendon.

This differential origin of the muscles forms the basis for the Silfverskiold test, which specifically measures gastrocnemius contracture by alternately relaxing and incorporating the muscle because of its origin proximal to the knee joint [11]. Keeping the subtalar joint neutral with the knee being extended, the ankle joint is passively dorsiflexed. The amount of ankle dorsiflexion is noted. The knee is then flexed with the ankle still passively dorsiflexed with the subtalar joint neutral. Any improvement in ankle dorsiflexion is then recorded. Any improvement in the ankle dorsiflexion when the knee is flexed compared to that when the knee is extended, is attributed to the tight gastrocnemius as flexing the knee relaxes the gastrocnemius, rather than the triceps surae complex.

The sural nerve is a sensory nerve formed by branches of the tibial nerve and the common peroneal nerve. Commonly, these are the medial sural cutaneous nerve and the peroneal communicating nerve; however variations in its formation exist. The nerve then runs down the posterior lateral aspect of the gastro-soleus complex and subsequently, the lateral border of the Achilles tendon. It supplies the posterior-lateral aspect of the leg, the lateral foot and the fifth toe [9] Injury to the sural nerve can result in sensory disturbances to the territory it supplies and a painful neuroma.

Based on our results, the sural nerve crosses the lateral border of the Achilles tendon at a point no more than 14 cm proximal to the calcaneal tuberosity, with an average distance of 9.9cm (Fig. 3). This correlates well with other previous studying looking at the anatomy of the sural nerve [9]. Thus, it is generally safe to place posterolateral incisions at least 14cm proximal to the calcaneal tuberosity if a posterolateral incision is planned for an endoscopic recession. However, injuries to the sural nerve during the gastrocnemius recession is still possible as it lies posterior to the Achilles tendon

and gastrocnemius tendon proximal to where it crosses the lateral border (Table 1).

Table 1. Measurements of Sural Nerve and Gastrocnemius Tendon.

Cadaver	Laterality	Distance from calcaneal tuberosity to the sural nerve where it crosses the lateral border of Achilles tendon	Distance from calcaneal tuberosity to the insertion of gastrocnemius tendon into Achilles tendon
1	Right	13cm	25cm
2	Left	8cm	18cm
3	Right	9cm	17cm
4	Right	8cm	18cm
5	Right	11cm	18cm
6	Right	10cm	17cm
7	Left	10cm	19cm
8	Left	14cm	22cm
9	Left	10cm	18cm
10	Left	7cm	22cm
11	Left	9cm	25cm
12	Right	10cm	20cm
Mean		9.9cm	19.9cm
Median		10cm	18.5cm

Our results also showed that the distance in which the gastrocnemius tendon insertions into the Achilles tendon is highly variable, ranging from 17 to 25cm. Based on our cadaveric study, using the calcaneal tuberosity as a guide to where the gastrocnemius tendon inserts into the Achilles tendon may not be reliable. A study by Pinney *et al.* [12] on patients who underwent the Strayer procedure through a posteromedial incision showed that the junction ranged from 10.7 to 20.9cm from the calcaneal tuberosity, with an average of 15.9cm. The ratio of this distance to the length of the leg was also variable from 0.33 to 0.6. It has been suggested that this junction is usually 18mm below the gastrocnemius indentation in this study and this is recommended as a landmark for making the posteromedial incision 2cm distal to the indentation and dissecting proximally.

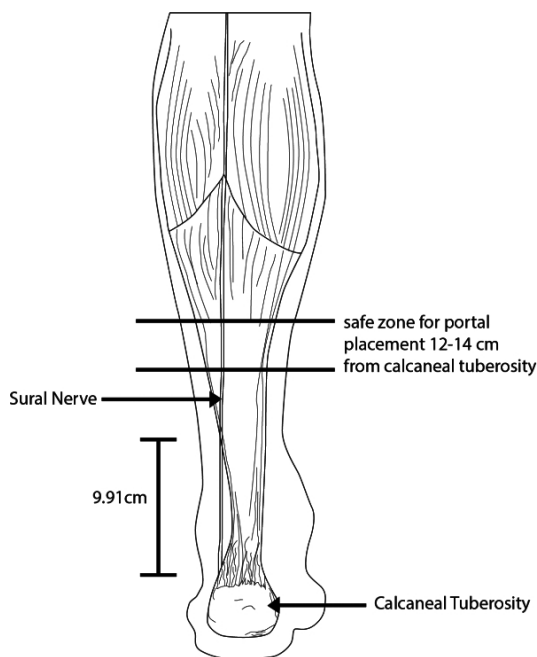


Fig. (3). Safe zone for endoscopic portal placement.

CONCLUSION

The strength of our study is that, it is based on human cadaveric specimens, which gives good representation of the location of the sural nerve that could be injured intra-operatively in actual practice. Nonetheless, it is limited by small number of cadaveric specimens.

ETHICS APPROVAL AND CONSENT TO PARTICIPATE

Not applicable.

HUMAN AND ANIMAL RIGHTS

No Animals/Humans were used for studies that are base of this research.

CONSENT FOR PUBLICATION

Not applicable.

CONFLICT OF INTEREST

The authors declare no conflict of interest, financial or otherwise.

ACKNOWLEDGEMENTS

Declared none.

REFERENCES

- [1] Strayer LM Jr. Recession of the gastrocnemius; an operation to relieve spastic contracture of the calf muscles. *J Bone Joint Surg Am* 1950; 32-A(3): 671-6.
[<http://dx.doi.org/10.2106/00004623-195032030-00022>] [PMID: 15428491]
- [2] Chimera NJ, Castro M, Manal K. Function and strength following gastrocnemius recession for isolated gastrocnemius contracture. *Foot Ankle Int* 2010; 31(5): 377-84.
[<http://dx.doi.org/10.3113/FAI.2010.0377>] [PMID: 20460063]
- [3] Duthon VB, Lübbecke A, Duc SR, Stern R, Assal M. Noninsertional Achilles tendinopathy treated with gastrocnemius lengthening. *Foot Ankle Int* 2011; 32(4): 375-9.
[<http://dx.doi.org/10.3113/FAI.2011.0375>] [PMID: 21733439]
- [4] Patel A, DiGiovanni B. Association between plantar fasciitis and isolated contracture of the gastrocnemius. *Foot Ankle Int* 2011; 32(1): 5-8.
[<http://dx.doi.org/10.3113/FAI.2011.0005>] [PMID: 21288428]
- [5] Tashjian RZ, Appel AJ, Banerjee R, DiGiovanni CW. Endoscopic gastrocnemius recession: Evaluation in a cadaver model. *Foot Ankle Int* 2003; 24(8): 607-13.
[<http://dx.doi.org/10.1177/107110070302400807>] [PMID: 12956566]
- [6] Herzenberg JE, Lamm BM, Corwin C, Sekel J. Isolated recession of the gastrocnemius muscle: The Baumann procedure. *Foot Ankle Int* 2007; 28(11): 1154-9.
[<http://dx.doi.org/10.3113/FAI.2007.1154>] [PMID: 18021583]
- [7] Chen L, Greisberg J. Achilles lengthening procedures. *Foot Ankle Clin* 2009; 14(4): 627-37.
[<http://dx.doi.org/10.1016/j.fcl.2009.08.002>] [PMID: 19857837]
- [8] Trevino S, Gibbs M, Panchbhavi V. Evaluation of results of endoscopic gastrocnemius recession. *Foot Ankle Int* 2005; 26(5): 359-64.
[<http://dx.doi.org/10.1177/107110070502600503>] [PMID: 15913518]
- [9] Webb J, Moorjani N, Real ford M. Anatomy of the sural nerve and its relation to the Achilles tendon. *Foot Ankle Int* 2000; 21(3): 475-7.
- [10] Rush SM, Ford LA, Hamilton GA. Morbidity associated with high gastrocnemius recession: retrospective review of 126 cases. *J Foot Ankle Surg* 2006; 45(3): 156-60.
[<http://dx.doi.org/10.1053/j.jfas.2006.02.006>] [PMID: 16651194]
- [11] Haddad SL, Deland JT. *Pes Planus Mann's Surgery of the Foot and Ankle*. 9th ed. Elsevier Saunders 2014.
- [12] Pinney Stephen J, Sangeorzan Bruce J, Hansen Sigvard T. Surgical anatomy of the gastrocnemius recession (Strayer Procedure). *Foot Ankle Int* 2004; 25(4): 247-50.
[PMID: 15132933]