



# The Open Orthopaedics Journal

Content list available at: <https://openorthopaedicsjournal.com>



## RESEARCH ARTICLE

### Comparison of Radiographic and Ultrasonographic Findings of Medial Elbow Laxity in High School Baseball Players

Mikio Harada<sup>1,\*</sup>, Masatoshi Takahara<sup>2</sup>, Masahiro Maruyama<sup>1</sup>, Junya Sasaki<sup>1</sup>, Hiroshi Satake<sup>1</sup>, Tomohiro Uno<sup>1</sup>, Nariyuki Mura<sup>3</sup> and Michiaki Takagi<sup>1</sup>

<sup>1</sup>Department of Orthopedic Surgery, Yamagata University Faculty of Medicine, Iida-Nishi-2-2-2, Yamagata, 990-9585 Japan

<sup>2</sup>Center for Hand, Elbow, and Sports Medicine, Izumi Orthopedic Hospital, Kamiyagari-Maruyama-6-1, Sendai, 981-3121 Japan

<sup>3</sup>Department of Orthopedic Surgery, Yoshioka Hospital, Higashi-Honcho-3-5-21, Tendo, 994-0026 Japan

#### Abstract:

#### Background:

Although ultrasonography has been used to assess medial elbow laxity, its usefulness has not yet been confirmed.

#### objective:

The aim of this study were to assess medial elbow laxity in high school baseball players based on measurements of the medial joint space (MJS) of the elbow using ultrasonography and radiography and to investigate the correlation between these assessments.

#### Methods:

Thirty-two high school baseball players participated in this study. Fourteen players (44%) were diagnosed with Ulnar Collateral Ligament (UCL) injury. Valgus stress was applied to the elbow by gravity during ultrasonographic and radiographic assessments, and the MJS was measured. The MJS of the throwing side was compared with that of the non-throwing side, and the increase in the MJS of the throwing side was determined. The correlation between ultrasonographic and radiographic assessments was investigated and the usefulness of these assessments for the diagnosis of UCL injury was evaluated.

#### Results:

A moderate correlation was found between the ultrasonographic and radiographic assessments of the MJS of the throwing side (correlation coefficient=0.547, P=0.0009). Furthermore, a weak correlation was found for the increase in MJS (correlation coefficient=0.348, P=0.0505), although it was not significant. The comparisons of the radiographic assessments between the UCL injury and non-UCL injury groups showed a significant difference in both the MJS of the throwing side (P=0.0068) and the increase in the MJS (P=0.02), although no difference was found using ultrasonography.

#### Conclusion:

Ultrasonography, similar to radiography, is useful for assessing medial elbow laxity. While radiography is useful for diagnosing UCL injury.

**Keywords:** Ultrasonography, Radiography, Elbow, Gravity, Laxity, Baseball.

#### Article History

Received: February 23, 2020

Revised: June 7, 2020

Accepted: June 8, 2020

## 1. INTRODUCTION

Valgus stress radiography, for which the force can be applied manually [1], with a Telos device [2 - 8], or by gravity [1, 5, 9, 10], has been reported as a quantitative means of

assessing medial elbow laxity. Recently, ultrasonography was used to assess medial elbow laxity [11 - 18]. However, the correlation between ultrasonographic and radiographic assessments has not been examined yet. It was hypothesized that ultrasonography, similar to radiography, would be useful for assessing medial elbow laxity. The aims of this study were to assess medial elbow laxity in high school baseball players using ultrasonography and radiography, to investigate the

\* Address correspondence to this author at the Department of Orthopedic Surgery, Yamagata University Faculty of Medicine Iida-Nishi-2-2-2, Yamagata, 990-9585 Japan; Tel: 81-23-628-5355; Fax: 81-23-628-5357; E-mail: miharadaeye@yahoo.co.jp

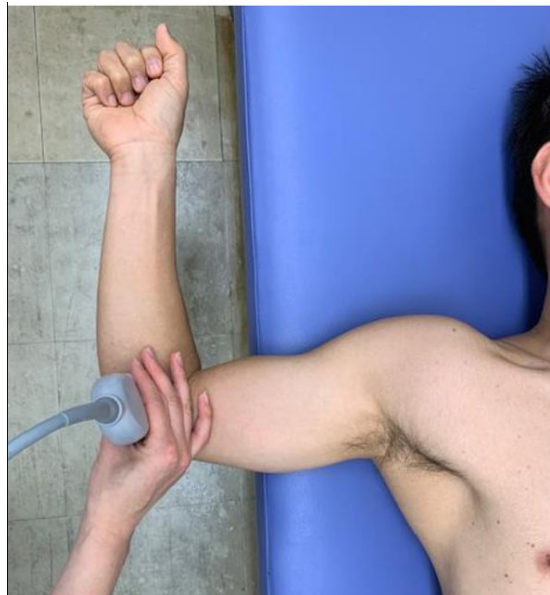
correlation between ultrasonographic and radiographic assessments, and to address the usefulness of ultrasonography.

## 2. MATERIALS AND METHODS

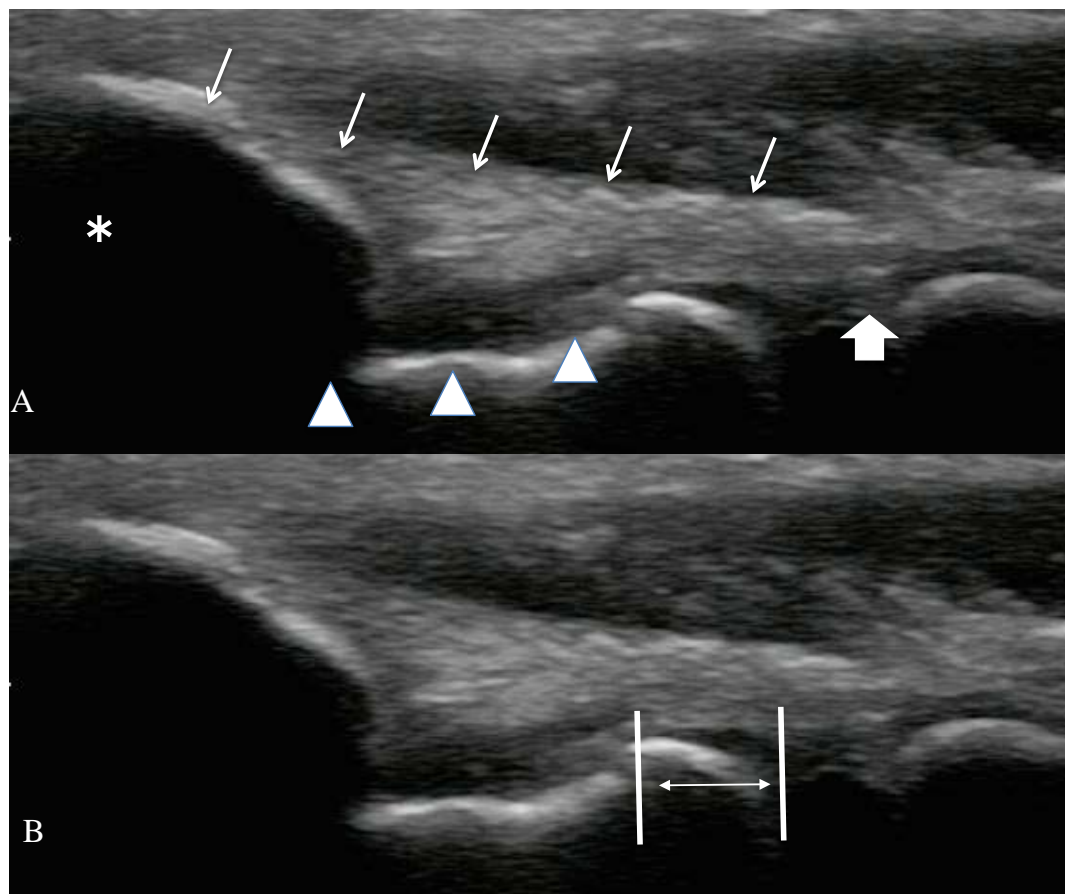
A prospective cohort study was conducted to assess medial elbow laxity. Institutional review board approval was obtained prior to starting the study, and informed consent was obtained from all subjects. A medical examination of the elbow was performed after the fall baseball season had ended for all high school baseball teams in the city, and the coach of each team selected two players on the team, mostly pitchers, to participate in the medical examination. The subjects in this study were 32 male high school baseball players who underwent a medical examination of the elbow in two hospitals, where two orthopedic surgeons performed ultrasound imaging of the medial aspect of the elbow. The 32 subjects underwent both valgus stress ultrasonography and valgus stress radiography, with force applied by gravity. The participants were aged between 15 and 18 years (mean, 16.0 years). Twenty-seven subjects had medial elbow pain when throwing, 27 had difficulty in pitching, and 15 had a positive moving valgus stress test [19].

For both ultrasonography and radiography, subjects were placed supine on a table with the shoulder in 90 degrees of abduction, and a valgus force was applied to the elbow via stress from gravity to assess medial elbow laxity. Ultrasound imaging of the medial aspect of the elbow was performed by 2 of the authors (M.T. and M.H.), both orthopedic surgeons with more than 10 years of experience in diagnosing throwing elbow injuries by ultrasonography. The ultrasound imaging was also performed using a 10-MHz annular array transducer (Hitachi, Hivision Avius, Tokyo, Japan). For ultrasonographic

examinations, as described in Sasaki *et al.*'s [16] report, subjects were placed supine on a table with the shoulder at 90 degrees of abduction and externally rotated, the elbow at 90 degrees of flexion, and the forearm in a neutral position, while the coronal aspect of the medial elbow was imaged (Fig. 1). The horizontal distance between the distal-medial corner of the trochlea and the proximal edge of the medial tubercular portion of the coronoid process was measured, and this measurement was considered to be the Medial Joint Space (MJS) of the elbow (Fig. 2). For measurement of the MJS, the ultrasonographic images were enlarged to electronically obtain MJS measurements that were accurate to within 0.1 mm (Hitachi, Hivision Avius, Tokyo, Japan). For radiographic assessments, as described in a previous report [5], subjects were placed supine on a table with the shoulder at 90 degrees of abduction and externally rotated, the elbow at 60 degrees of flexion, and the forearm in a neutral position, while anteroposterior radiographs were obtained (Fig. 3). A polystyrene foam frame was placed under the upper arm proximal to the elbow so that a valgus force was easily applied via stress from gravity. The shortest distance between the most distal point on the curved contour of the medial epicondyle and the ulnar coronoid process was measured, and this measurement was considered to be the MJS (Fig. 4). The anteroposterior radiographs were enlarged to obtain MJS measurements accurate to within 0.01 mm using software (Vox-Base, J-mac system, Sapporo, Japan). The MJS measurement of both ultrasonography and radiography was performed once. For both ultrasonography and radiography, the MJS on the throwing side was compared with that on the non-throwing side, and the increase in the MJS on the throwing side was determined.



**Fig. (1).** Photograph depicting the technique used for valgus stress ultrasonography using gravity. Subjects were placed supine on a table with the shoulder in 90 degrees of abduction, the elbow in 90 degrees of flexion, and the forearm in a neutral position; the coronal aspect of the medial elbow is displayed.



**Fig. (2).** Ultrasonographic image of the medial elbow. A. Ultrasonographic images including both the top of the humeral medial epicondyle (asterisk) and the medial tubercular portion of the ulnar coronoid process (large arrow) are displayed simultaneously. The ulnohumeral joint space is observed as an anechoic space between the trochlea (arrowhead) and the coronoid process. The ulnar collateral ligament (UCL) (arrow) is identified as a band-like structure that attached to the medial epicondyle and the tubercular portion of the coronoid process. B. The horizontal distance between the distal-medial corner of the trochlea and the proximal edge of the medial tubercular portion of the coronoid process was measured, and this measurement was considered the medial joint space (MJS) of the elbow (arrows).

First, ultrasonography was performed. Second, radiography was performed without knowledge of the results of the ultrasonography. Finally, without knowledge of the results of the ultrasonography and radiography, the presence of medial elbow pain or difficulty pitching was questioned, and the moving valgus stress test was performed. The correlation between the MJS on ultrasonographic and radiographic assessments, and the correlation between the increase in the MJS on ultrasonographic and radiographic assessments were investigated. Additionally, ulnar collateral ligament (UCL) injury was considered to be present when the following three conditions were met: (1) medial elbow pain, (2) difficulty in pitching, and (3) a positive result on the moving valgus stress test. UCL injury (the basis for defining the UCL injury group) was found in 14 subjects. The increase in the MJS between the UCL injury group and the non-UCL injury group on ultrasonographic and radiographic assessments was compared to determine the usefulness of each assessment for the diagnosis of UCL injury.

### 2.1. Statistical Analysis

In the investigation of the correlation between ultrasonographic and radiographic measurements, statistical

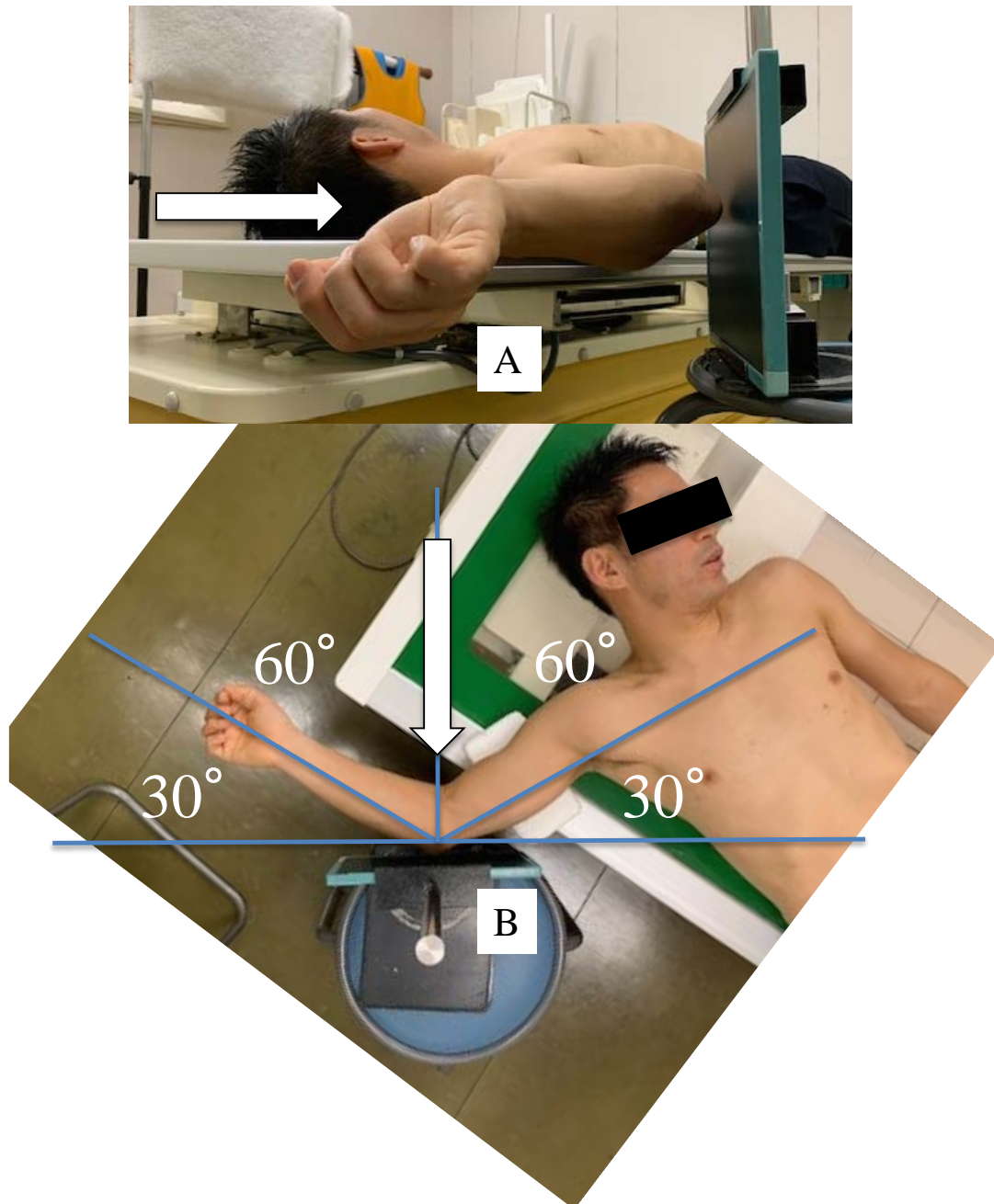
analysis of the data was conducted using Spearman's correlation coefficient. The outcome results were interpreted according to the degree of association as very strong (0.8–1), strong (0.6–0.79), moderate (0.40–0.59), weak (0.20–0.39), or very weak (0.00–0.19), after significant correlation values ( $P < 0.05$ ) were considered. To compare the MJS or the increase in the MJS on ultrasonographic and radiographic assessments between the UCL injury ( $n=14$ ) and non-UCL injury ( $n=18$ ) groups, statistical analysis was conducted using the Mann-Whitney U test and Fisher's exact test. Differences with a value of  $P < 0.05$  were considered significant. The cut-off value was derived from Receiver Operating Characteristic (ROC) curve analysis. The accuracy of the diagnosis of UCL injury was evaluated by calculating the Area Under The Curve (AUC). The level of significance was defined as  $P < 0.05$ . The data were expressed as the mean value and standard deviation. Statistical analysis was performed using EZR (Saitama Medical Center Jichi Medical University, Saitama, Japan).

### 3. RESULTS

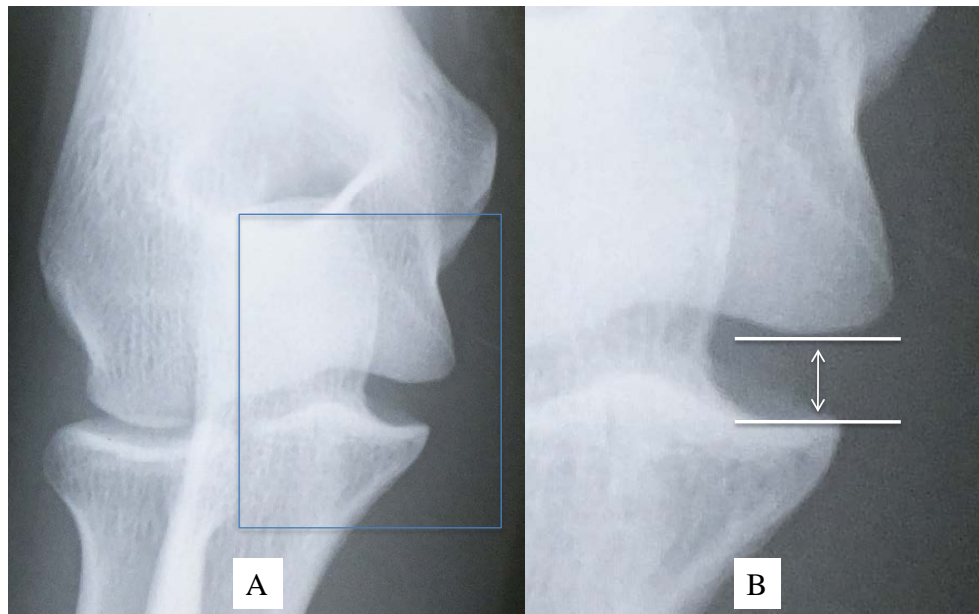
The ultrasonographic assessments showed that the mean MJS was  $4.2 \pm 0.9$  mm (range, 1.9–6.4 mm) on the throwing side and  $3.3 \pm 1.0$  mm (range, 1.1–5.2 mm) on the non-throwing

side and that the mean increase in the MJS of the throwing side was  $0.9 \pm 0.5$  mm (range,  $-1.0$ – $3.0$  mm) ( $P < 0.01$ ). The radiographic assessments showed that the mean MJS was  $4.8 \pm 0.8$  mm (range,  $3.0$ – $7.2$  mm) on the throwing side and  $3.8 \pm 1.1$  mm (range,  $2.1$ – $5.7$  mm) on the non-throwing side and that the mean increase in the MJS of the throwing side was  $1.0 \pm 0.6$  mm (range,  $-0.5$ – $2.8$  mm) ( $P < 0.01$ ). For the MJS of the

throwing side, a moderate correlation was found between the ultrasonographic and radiographic measurements (correlation coefficient= $0.547$ ,  $P=0.0009$ ) (Table 1, Fig. 5a). Furthermore, a weak correlation tended to be found for the increase in the MJS of the throwing side (correlation coefficient= $0.348$ ,  $P=0.0505$ ), although it was not significant (Table 1, Fig. 5b).



**Fig. (3).** Photograph depicting the technique used for valgus stress radiography using gravity. A. Lateral view. Anteroposterior radiographs were obtained as gravity stress was applied to the elbow. The direction of X-ray exposure (arrow) is shown. B. Anteroposterior view. Subjects were placed supine on a table with the shoulder in 90 degrees of abduction, the elbow in 60 degrees of flexion, and the forearm in a neutral position. An elbow flexion angle of 60 degrees was ensured using a triangular polystyrene foam frame set at the correct angle. The direction (arrow) and angle of X-ray exposure are shown.



**Fig. (4).** Radiographic image of the elbow. a. A representative anterior-posterior radiographic image of the elbow. B. Magnification of the radiographic image of the elbow. The shortest distance between the most distal point on the curved contour of the medial epicondyle and the ulnar coronoid process was measured, and this distance was considered the medial joint space (MJS) of the elbow (arrows).

**Table 1. Correlation between the ultrasonographic and radiographic measurements of the medial joint space.**

	Ultrasonography	Radiography	Correlation Coefficient	P-value
Throwing side	4.2 ± 0.9 mm	4.8 ± 0.8 mm	0.547	0.0009
Non-throwing side	3.3 ± 1.0 mm	3.8 ± 1.1 mm	0.296	0.10
Increase in the MJS*	0.9 ± 0.5 mm	1.0 ± 0.6 mm	0.348	0.05

\* Increase in the MJS (medial joint space) on the throwing side.

The ultrasonographic assessment showed that the mean MJS of the throwing side was 4.5 mm (range, 2.5–6.2 mm) in the UCL injury group and 4.1 mm (range, 1.9–6.4 mm) in the non-UCL injury group. No difference was found in the ultrasonographic assessments of the MJS of the throwing side between the UCL injury and non-UCL injury groups (P=0.374). Although no statistically significant cut-off value could be obtained, the MJS of the throwing side with the highest specificity (0.778) and sensitivity (0.5) was 4.7 mm (Fig. 5a). The AUC of the ROC curves for UCL injury was 0.591 (95% confidence interval: 0.384-0.799). Additionally, the mean increase in the ultrasonographic assessment of the

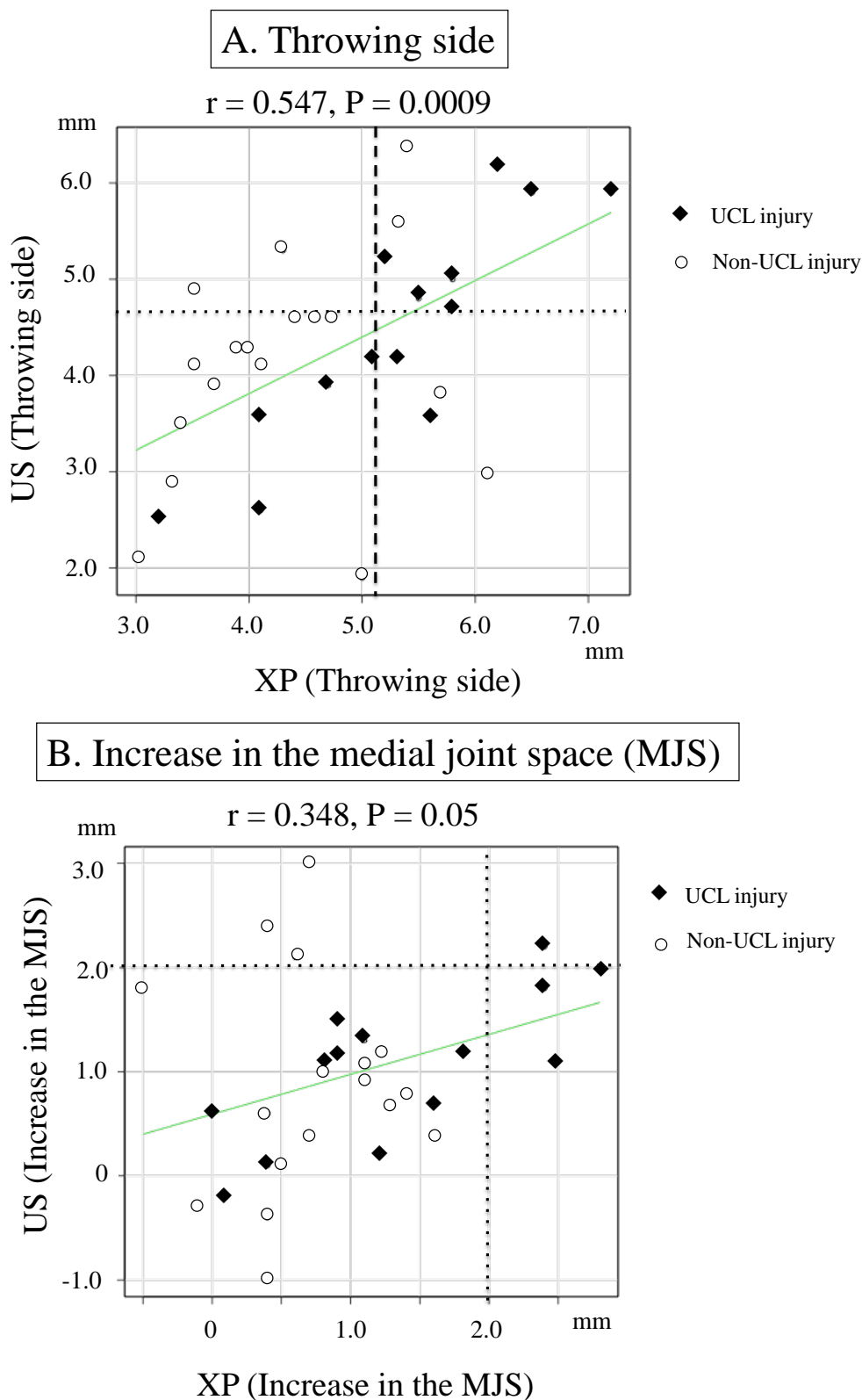
MJS of the throwing side was 1.0 mm (range, -0.2–2.2 mm) in the UCL injury group and 0.9 mm (range, -1.0–3.0 mm) in the non-UCL injury group. No difference was observed in the increase in the MJS between the UCL injury and non-UCL injury groups on ultrasonographic assessments (P=0.69). UCL injury was found in 2 out of 5 subjects with an MJS increase of 2.0 mm or more, whereas UCL injury was found in 12 out of 27 subjects with an MJS increase of 2.0 mm or less. There was no difference in the frequency of UCL injury between those patients with an increase of 2.0 mm or more in the MJS and those with an increase of 2.0 mm or less on ultrasonographic assessments (P=0.99) (Table 2).

**Table 2. Comparison of the increase in the medial joint space between UCL and non-UCL injury on ultrasonographic and radiographic assessments.**

		-	-	UCL* injury	-	Non-UCL injury	-
		-	-	N=14	-	N=18	
	Increase in the MJS*	-	N	N	-	N	P-value
Ultrasonography	2.0 mm or more	Yes	5	2	-	3	0.99
		No	27	12	-	15	-
Radiography	2.0 mm or more	Yes	4	4	-	0	0.02
		No	28	10	-	18	-

\* UCL (ulnar collateral ligament) injury was defined as the presence of elbow pain, difficulty throwing, and a positive result on the moving valgus stress test.

\*\* Increase in the MJS (medial joint space) on the throwing side.



**Fig. (5).** Correlation between ultrasonographic and radiographic measurements of the medial joint space (MJS). A. The MJS measurements on the throwing side showed a moderate correlation between ultrasonographic and radiographic assessments. B. The increase in the measured MJS of the throwing side exhibited a tendency toward a weak correlation, although it was not significant.

The radiographic assessment showed that the mean MJS of the throwing side was 5.3 mm (range, 3.2–7.2 mm) in the UCL injury group and 4.1 mm (range, 3.0–6.1 mm) in the non-UCL injury group. The MJS of the throwing side in the UCL injury group was significantly increased compared to that of the non-UCL injury group ( $P=0.0068$ ), and the cut-off value was 5.1 mm (specificity: 0.778, sensitivity: 0.714) (Fig. 5a). The AUC of the ROC curves for UCL injury was 0.770 (95% confidence interval: 0.596-0.944). Additionally, on the radiographic assessments, the mean increase in the MJS of the throwing side in the UCL injury group was 1.4 mm (range, 0–2.8 mm), and that in the non-UCL injury group was 0.7 mm (range, -0.5–1.6 mm). The increase in the MJS of the throwing side in the UCL injury group was significantly greater than that in the non-UCL injury group ( $P=0.02$ ). UCL injury was found in all 4 of the subjects who had an increase of 2.0 mm or more in the MJS, whereas UCL injury was found in 10 out of the 28 subjects who had an increase of 2.0 mm or less in the MJS. Statistical analysis showed that a significantly greater number of subjects with an increase of 2.0 mm or more in the MJS of the throwing side had a UCL injury ( $P<0.05$ ) (Table 2).

#### 4. DISCUSSION

In this study, the MJS of the throwing side showed a moderate correlation between the ultrasonographic and radiographic measurements, and the increase in the MJS of the throwing side exhibited a tendency toward a weak correlation, although it was not significant. These results suggest that ultrasonography, similar to radiography, is useful for assessing medial elbow laxity. This is the first study to suggest the usefulness of ultrasonography to assess medial elbow laxity in comparison with radiographic findings. The following two factors may have affected comparisons between ultrasonographic and radiographic assessments. Regarding the degree of elbow flexion, the elbow was in 60 degrees of flexion on radiographic assessment, whereas the elbow was in 90 degrees of flexion on ultrasonographic assessment. Regarding the measurement of the MJS, the shortest distance between the most distal point on the curved contour of the medial epicondyle and the ulnar coronoid process was measured on radiographic assessment, whereas the medial edge of the ulnohumeral joint was measured on ultrasonographic assessment. It is possible that the differences in these conditions might influence the correlation between ultrasonographic and radiographic assessments.

Regarding the usefulness of radiographic assessments for detecting UCL injury, the MJS of the throwing side in UCL injury group (mean 5.3 mm) was significantly increased compared to that in the non-UCL injury group (mean 4.1 mm), and the increase in the MJS of the throwing side in the UCL injury group (mean 1.4 mm) was significantly increased compared to that in the non-UCL injury group (mean 0.7 mm). Additionally, a significantly greater number of subjects with an increase in the MJS of 2.0 mm or greater had UCL injury. These results suggest that valgus stress radiography, via gravity, is useful for the diagnosis of UCL injury. In previous studies, medial elbow laxity was assessed using valgus stress radiography, which can be conducted either manually [1], with a Telos device [2 - 8], or by gravity [1, 5, 9, 10]. Another previous study also reported that, in 38 (88%) out of 43 subjects who underwent UCL reconstruction, the increase in

the MJS of the throwing side was 2.0 mm or more [20]. This and previous studies suggest that, in high school baseball players, an increase of 2 mm or more in the MJS of the throwing side was assessed as pathological medial elbow laxity, that is, medial elbow instability. However, on radiographic assessments, UCL injury was found to be present in 10 out of 28 subjects with an increase in the MJS of 2.0 mm or less. It was speculated that in cases with an increase in the MJS of 2.0 mm or less, the degree of UCL injury was slight, and, in subjects with UCL injury with an increase in the MJS of 2.0 mm or less, the period between the onset of symptoms and the medical examination was short.

In the radiographic assessment, a 5.1-mm cut-off value for the MJS of the throwing side for UCL injury had moderate accuracy because the AUC was 0.770, but the MJS of the throwing side is easily affected by body size. On the other hand, an increase in the MJS on the throwing side was not affected by body size, because the increase in the MJS was the difference between the MJS on the throwing side and that on the non-throwing side. Therefore, in the diagnosis of UCL injury, it is valid to use the increase in the MJS on the throwing side.

In this study, the ultrasonographic assessment of the MJS was correlated with the radiographic assessment, whereas the ultrasonographic assessment was not correlated with UCL injury. Because the medial edge of the ulnohumeral joint was measured on ultrasonography, the MJS may have been underestimated when an osteophyte was present on the medial edge of the ulna. Additionally, the ultrasonographic images were in cross-sections, and the evaluation depended on the image in the section that the examiner had assessed. In this study, only the MJS was measured and compared between ultrasonographic and radiographic assessments. However, ultrasonography has advantages for assessing not only the MJS but also the midsubstance of the UCL; thus, ultrasonography could be an effective supplemental tool for the diagnosis of UCL injury.

This study had several limitations. The first limitation is that the MJS measurement of both ultrasonography and radiography were performed only once. Although intra- and interobserver reliability of ultrasonography [16] and radiography [5] have been confirmed by the previous studies, the reliability of ultrasonography and radiography were not confirmed in this study. Second, there is the possibility of bias in the measurement of the MJS because two orthopedic surgeons performed ultrasound imaging of the elbow in two hospitals. That is, one orthopedic surgeon performed ultrasound imaging for half of the 32 subjects in one hospital, and the other surgeon performed imaging for the remaining half in another hospital. However, the bias was not considered to be high because both orthopedic surgeons had more than 10 years of experience in diagnosing throwing elbow injuries by ultrasonography. Finally, this study had a very small sample size. According to the results of a posthoc power analysis of the outcome, the power was 0.2633. Further investigations with large study populations and comparisons of two groups will be needed.

## CONCLUSION

Medial elbow laxity in 32 high school baseball players was assessed to investigate the correlation between ultrasonographic and radiographic assessments, as well as the usefulness of ultrasonography. A moderate correlation was found between the ultrasonographic and radiographic assessments of the MJS of the throwing side. Furthermore, a weak correlation tended to be found for the increase in the MJS, although it was not significant. These results suggest that ultrasonography, similar to radiography, is useful for assessing medial elbow laxity. The comparison of radiographic assessments between the UCL injury and non-UCL injury groups also showed a significant intergroup difference in both the MJS of the throwing side and the increase in the MJS, although no difference was found using ultrasonography. These results suggest that radiography is useful for diagnosing UCL injury.

## LIST OF ABBREVIATIONS

<b>MJS</b>	=	Medial Joint Space
<b>(UCL) injury</b>	=	Ulnar Collateral Ligament

## ETHICS APPROVAL AND CONSENT TO PARTICIPATE

Institutional review board approval was obtained before the start of this study, and informed consent was obtained from the subjects. The name of the approval-granting authority is the Ethical Committee of the Yamagata University Faculty of Medicine, and the study number is 220.

## HUMAN AND ANIMAL RIGHTS

Institutional review board approval was obtained before the start of this study, and informed consent was obtained from the subjects.

## CONSENT FOR PUBLICATION

I give my consent for the publication of this study.

## AVAILABILITY OF DATA AND MATERIALS

The data and materials supporting the findings of this article are available only in our study.

## FUNDING

None.

## CONFLICT OF INTEREST

The authors have no conflicts of interest to declare.

## ACKNOWLEDGEMENTS

Decalred none.

## REFERENCES

- [1] Lee GA, Katz SD, Lazarus MD. Elbow valgus stress radiography in an uninjured population. *Am J Sports Med* 1998; 26(3): 425-7. [http://dx.doi.org/10.1177/03635465980260031401] [PMID: 9617407]
- [2] Conway JE, Jobe FW, Glousman RE, Pink M. Medial instability of the elbow in throwing athletes. Treatment by repair or reconstruction of the ulnar collateral ligament. *J Bone Joint Surg Am* 1992; 74(1): 67-83. [http://dx.doi.org/10.2106/00004623-199274010-00009] [PMID: 1734015]
- [3] Ellenbecker TS, Mattalino AJ, Elam EA, Caplinger RA. Medial elbow joint laxity in professional baseball pitchers. A bilateral comparison using stress radiography. *Am J Sports Med* 1998; 26(3): 420-4. [http://dx.doi.org/10.1177/03635465980260031301] [PMID: 9617406]
- [4] Eygendaal D, Heijboer MP, Obermann WR, Rozing PM. Medial instability of the elbow: findings on valgus load radiography and MRI in 16 athletes. *Acta Orthop Scand* 2000; 71(5): 480-3. [http://dx.doi.org/10.1080/000164700317381171] [PMID: 11186405]
- [5] Harada M, Takahara M, Maruyama M, Nemoto T, Koseki K, Kato Y. Assessment of medial elbow laxity by gravity stress radiography: comparison of valgus stress radiography with gravity and a Telos stress device. *J Shoulder Elbow Surg* 2014; 23(4): 561-6. [http://dx.doi.org/10.1016/j.jse.2014.01.002] [PMID: 24630547]
- [6] Popovic N, Ferrara MA, Daenen B, Georis P, Lemaire R. Imaging overuse injury of the elbow in professional team handball players: a bilateral comparison using plain films, stress radiography, ultrasound, and magnetic resonance imaging. *Int J Sports Med* 2001; 22(1): 60-7. [http://dx.doi.org/10.1055/s-2001-11333] [PMID: 11258643]
- [7] Rijke AM, Goitz HT, McCue FC, Andrews JR, Berr SS. Stress radiography of the medial elbow ligaments. *Radiology* 1994; 191(1): 213-6. [http://dx.doi.org/10.1148/radiology.191.1.8134574] [PMID: 8134574]
- [8] Singh H, Osbahr DC, Wickham MQ, Kirkendall DT, Speer KP. Valgus laxity of the ulnar collateral ligament of the elbow in collegiate athletes. *Am J Sports Med* 2001; 29(5): 558-61. [http://dx.doi.org/10.1177/03635465010290050601] [PMID: 11573912]
- [9] Jobe FW, Stark H, Lombardo SJ. Reconstruction of the ulnar collateral ligament in athletes. *J Bone Joint Surg Am* 1986; 68(8): 1158-63. [http://dx.doi.org/10.2106/00004623-198668080-00004] [PMID: 3771597]
- [10] Woods GW, Tullos HS. Elbow instability and medial epicondyle fractures. *Am J Sports Med* 1977; 5(1): 23-30. [http://dx.doi.org/10.1177/036354657700500105] [PMID: 848632]
- [11] Bica D, Armen J, Kulas AS, Youngs K, Womack Z. Reliability and precision of stress sonography of the ulnar collateral ligament. *J Ultrasound Med* 2015; 34(3): 371-6. [http://dx.doi.org/10.7863/ultra.34.3.371] [PMID: 25715357]
- [12] De Smet AA, Winter TC, Best TM, Bernhardt DT. Dynamic sonography with valgus stress to assess elbow ulnar collateral ligament injury in baseball pitchers. *Skeletal Radiol* 2002; 31(11): 671-6. [http://dx.doi.org/10.1007/s00256-002-0558-0] [PMID: 12395281]
- [13] Harada M, Takahara M, Sasaki J, Mura N, Ito T, Ogino T. Using sonography for the early detection of elbow injuries among young baseball players. *AJR Am J Roentgenol* 2006; 187(6): 1436-41. [http://dx.doi.org/10.2214/AJR.05.1086] [PMID: 17114533]
- [14] Hendawi TK, Rendos NK, Warrell CS, et al. Medial elbow stability assessment after ultrasound-guided ulnar collateral ligament transection in a cadaveric model: ultrasound versus stress radiography. *J Shoulder Elbow Surg* 2019; 28(6): 1154-8. [http://dx.doi.org/10.1016/j.jse.2018.11.060] [PMID: 30770313]
- [15] Nazarian LN, McShane JM, Ciccotti MG, O'Kane PL, Harwood MI. Dynamic US of the anterior band of the ulnar collateral ligament of the elbow in asymptomatic major league baseball pitchers. *Radiology* 2003; 227(1): 149-54. [http://dx.doi.org/10.1148/radiol.2271020288] [PMID: 12616000]
- [16] Sasaki J, Takahara M, Ogino T, Kashiwa H, Ishigaki D, Kanauchi Y. Ultrasonographic assessment of the ulnar collateral ligament and medial elbow laxity in college baseball players. *J Bone Joint Surg Am* 2002; 84(4): 525-31. [http://dx.doi.org/10.2106/00004623-200204000-00003] [PMID: 11940610]
- [17] Shanley E, Smith M, Mayer BK, et al. Using stress ultrasonography to understand the risk of UCL injury among professional baseball pitchers based on ligament morphology and dynamic abnormalities. *Orthop J Sports Med* 2018; 6(8)2325967118788847 [http://dx.doi.org/10.1177/2325967118788847] [PMID: 30116762]
- [18] Ward SI, Teefey SA, Paletta GA Jr, et al. Sonography of the medial collateral ligament of the elbow: A study of cadavers and healthy adult male volunteers. *AJR Am J Roentgenol* 2003; 180(2): 389-94. [http://dx.doi.org/10.2214/ajr.180.2.1800389] [PMID: 12540439]
- [19] O'Driscoll SW, Lawton RL, Smith AM. The "moving valgus stress test" for medial collateral ligament tears of the elbow. *Am J Sports Med* 2005; 33(2): 231-9.



[<http://dx.doi.org/10.1177/0363546504267804>] [PMID: 15701609]  
[20] Thompson WH, Jobe FW, Yocum LA, Pink MM. Ulnar collateral ligament reconstruction in athletes: Muscle-splitting approach without

transposition of the ulnar nerve. J Shoulder Elbow Surg 2001; 10(2): 152-7.  
[<http://dx.doi.org/10.1067/mse.2001.112881>] [PMID: 11307079]

---

© 2020 Harada *et al.*

This is an open access article distributed under the terms of the Creative Commons Attribution 4.0 International Public License (CC-BY 4.0), a copy of which is available at: <https://creativecommons.org/licenses/by/4.0/legalcode>. This license permits unrestricted use, distribution, and reproduction in any medium, provided the original author and source are credited.